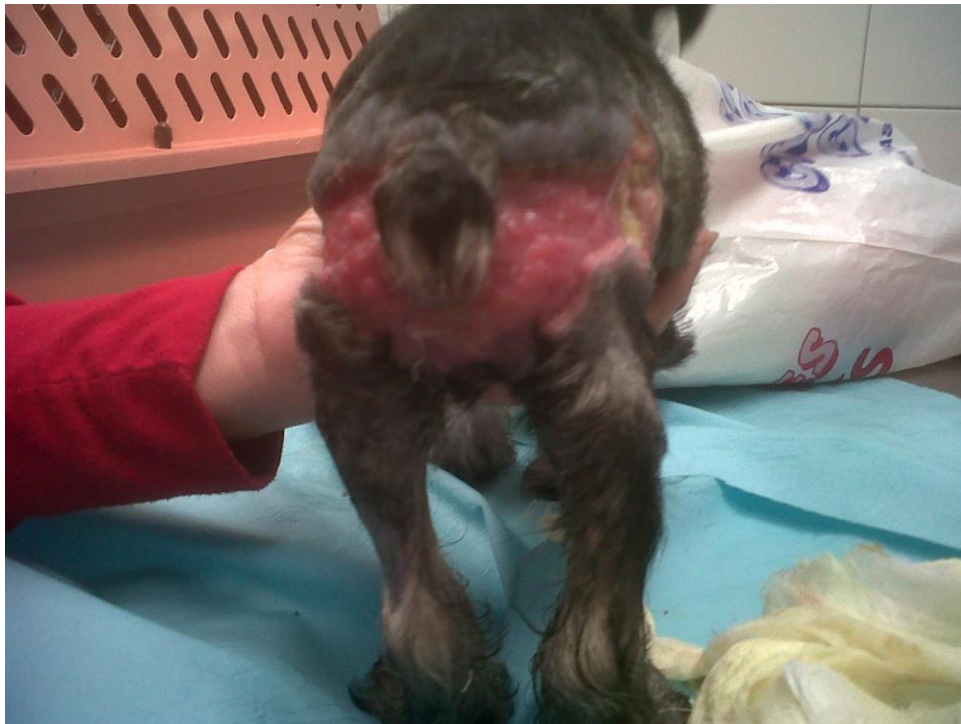

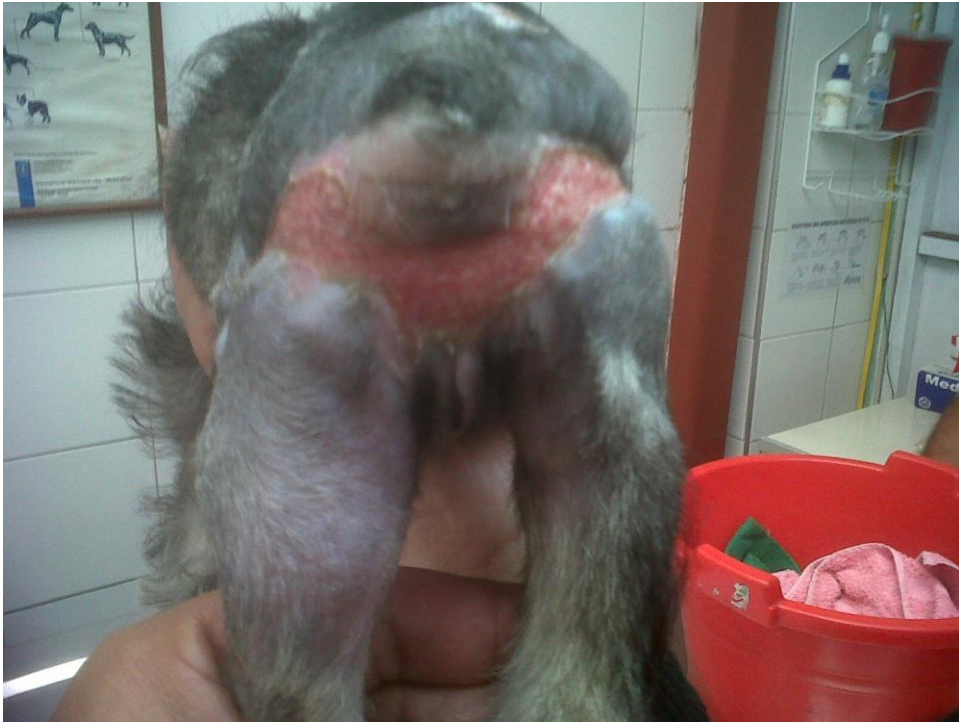
TREATMENTS DERMATOLOGICAL WITH Electrolyzed Water Or ANOLYTE HOCl



Male Schnauzer of 3 months; it began with one slight irritation around the anus and not quick attention. The infected irritation detected by the veterinarian was early stages of necrosis of skin and muscle. The problem extended from the abdomen and to the testicles. Several other diverse products and healing creams were used to combat the infection but failed to heal it.

Electrolyzed Water was then introduced as see in this photo applying it six times per day to the entire infected area.

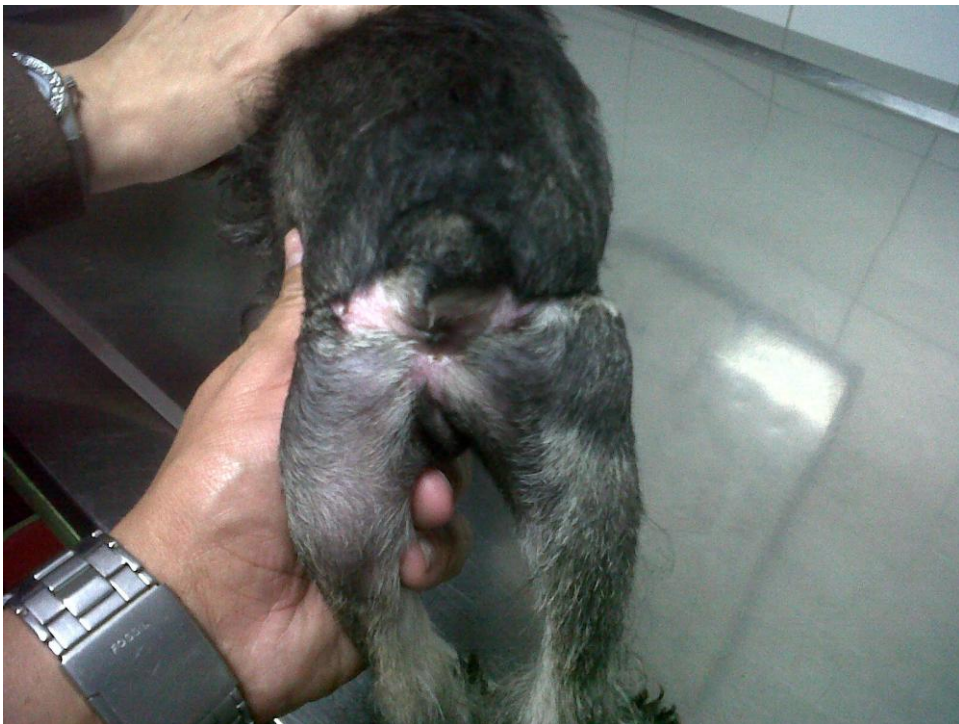DAY 8 of Electrolyzed Water Treatment



This photo represents **Day 8** of treatment with electrolyzed water showing significant improvement of infected area showing significant healing signs

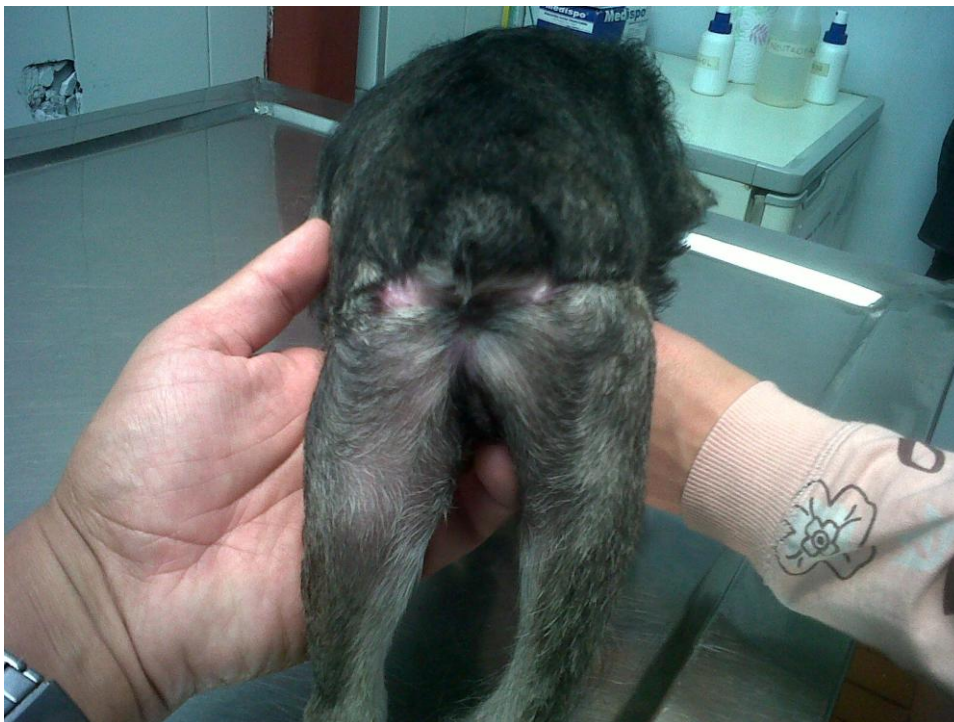Spray application was reduced to 3 times per day and all antibiotics were discontinued

DAY 30 of Electrolyzed Water Treatment



This photo represents **Day 30** of treatment with Hypochlorous acid showing significant improvement of all zone damaged, without signs of infection.

DAY 38 of Electrolyzed Water Treatment Completely Recovered



This photo represents **Day 38** of treatment with Electrolyzed Water showing complete recovery